

## **An Appeal from a helpless Father for his Son**

Beloved Brother/Sister,

Date:10/03/2015

This is a humble request from a helpless father and mother who has brought up children like all parents. I am Thomas Chacko and my wife is Leelamma Chacko. We had three children. Misfortune struck us long back when our elder son left us and taken to heavenly abode when he died in a Railway Accident when he was about 5 years of age. And to add to our great despair our youngest son Reny Chacko who is just 30 years met with a very serious road accident in the wee hour of New Year Day 2015. My child was working as a Dialysis Technician at Apollo BSR Hospital, Bhilai Chhattisgarh. On the morning of that disastrous day some unknown vehicle hit my son who was driving a bike. He has badly damaged his lower abdomen and pelvic area. He was treated in the same hospital where he was working (Apollo BSR Hospital, Bhilai).

However Almighty God gave him to us. We are really thankful to him. From then onwards he has underwent more than 8 surgeries in less than 2 months a few of them major ones. His condition brings tears to our eyes. But we have to accept all that God brings our way. We are glad that his health is improving. The doctors are keeping a very positive hope. He has now been shifted from Apollo BSR Hospital, Bhilai to C M C Hospital Vellore for getting more expert hands and better treatment. He was brought by road on an Ambulance.

Basically we are from Kurichy in Kottayam. We belong to an average income family who used to just run our house. The hearty support from various organizations and individuals has made us see this day. One of our sons Kuruvilla is working day in and day out to support his younger brother. We are very much sure that Almighty Lord who has given him to us till this day will never forsake us.

Being the parent of a bed ridden son we do not have any other option rather than to earnestly request all the good hearted friends to pray for my son and also to extend some monetary support that you can to support us. Till now we have already spend an amount of Rs.12.Lakhs. Further the doctor from C M C Hospital Vellore has said that we may need an additional of Rs.15 Lakhs more for his treatment which includes a number of surgeries and even a plastic surgery. Hoping your kind support and prayers. I am attaching our Phone Nos and Bank Details.

Thomas Chacko

0091-9497126314 (In Kerala/Father)

00919496136404 (In Vellore/Mother)

### **Bank Details:**

THOMAS CHACKO  
A/C No: 6718124362  
State Bank Of Travancore . ,KURICHY,  
KOTTAYAM  
I F C CODE 0000262

**ADDRESS** : RENY CHACKO [ 30YEARS]  
VAZHAPARAMBIL HOUSE  
KURICHY ,P.O. ,KOTTAYAM , 686549

**PARISH** : ST.MARYS & ST.JOHSN  
ORTHODOX CHURCH  
KURICHY . KOTTAYAM



### GENERAL DISCHARGE SUMMARY

Reg No.	10129563	IP No.	15/104940
Patient	Mr. Benny Chakk(Staff)	Bed Category	Twin Room
Age / Sex	30 Yrs/Male	Bed No.	223-A
Consultant	Dr. ASHISHKUMAR SHRIVASTAVA	DOA	01/01/2015 06:57
Surgery Date	23/01/2015 15:13	DOO	
Address	VAZTUPARAMBI, SPURAM KURICH Kerala INDIA		

#### DIAGNOSIS

Fracture pelvis, fracture acetabulum, pelvic open book fracture, pubic diastasis, fracture M/3rd femur with fracture IT right, Fracture sacrum with right SI joint disreption.

#### HISTORY

Alleged history of RTA on 01/01/2015 at 07:00 AM, hit by unknown vehicle  
History of unconscious.  
Pelvic open injury; internal organ & Bone exposed.

#### CLINICAL EXAMINATION

RI LL in exp. - Thigh deformity +ve.  
- Crepitus +ve  
- Abnormal mobility +ve.

#### TREATMENT GIVEN

- Pubic symphysis stabilisation with plating right sup.pubic rammi on 03/01/2015 by Dr. S.J. Shirguppe.  
- ORIF with recon nail right for 2 months old IT fracture right with fracture m/3rd femur right on 21/02/2015 by Dr. S.J. Shirguppe.

#### INVESTIGATIONS

X-ray right foot - Fracture head of 2nd, 3rd & 4th metatarsals noted.  
X-ray right femur - Fracture neck shift of right femur seen.  
Arterial color doppler - Normal triphasic flow in right superficial femoral artery, popliteal artery anterior tibia artery ant. tibial artery & DP artery.  
- Normal phasic flow with colour filling seen in deep venous system.  
- Subcutaneous edema seen in right foot region.

#### COURSE IN THE HOSPITAL AND DISCUSSION (Including procedure/ surgery performed)

A 30 years old male patient presented with alleged history of RTA on 01/01/2015 at 07:00 AM, hit by unknown vehicle. History of unconscious. Pelvic open injury; internal organ & Bone exposed, admitted under Dr. A.K. Shrivastava. Required investigation were done. - Pubic symphysis stabilisation with plating right sup.pubic rammi on 03/01/2015 by Dr. S.J. Shirguppe & ORIF with recon nail right for 2 months old IT fracture right with fracture m/3rd femur right on 21/02/2015 by Dr. S.J. Shirguppe. Post operative patient recovered well. Now patient discharge on haemodynamically stable condition.

**PROCEDURE / SURGERY PERFORMED**

pubic-symphysis stabilisation with plating right sup. pubic ramus on 03/01/2015 by Dr. S.J. Shirguppe.  
ORIF with recon nail right for 2 months old IT fracture right with fracture m/3rd femur right on  
02/2015 by Dr. S.J. Shirguppe.

**CONDITION OF THE PATIENT AT THE TIME OF DISCHARGE**

hemodynamically stable.

**ADVICE ON DISCHARGE**

DIET - Normal

PHYSICAL ACTIVITY - As tolerated.

**DISCHARGE MEDICATION**

Rx:

Tablet - Bone K2 once daily x 1 month

Tablet - A to Z once daily x 1 month

Tablet - Ultracet 1-----1 (SOS) if require for pain

**FOLLOW UP**

- Review after

**URGENT CARE**

**HOW TO OBTAIN**

In the emergency, contact casualty medical officer. Emergency contact No: Phone: 0788-4085100-299.  
This discharge summary was explained to me in my own language which I understand and handed over  
to me by the consultant.

Signature of Patient/Patient relatives:      Signature of the Doctor      Registrar/Resident/C.M.O.

ORIF with recon nail right for 2 months old IT fracture right with fracture w/dry fracture right on  
 21/02/2015(SS)  
 Bladder closure with bilateral ureteric catheter placement on 24.2.15 by AVD

**INVESTIGATION** (At the time of discharge)

CBC - Hb - 9.3, TLC - 6110, platelet count - 309000/mm<sup>3</sup>  
 UCT - Urea - 18mg/dl, creatinine - 0.92 mg/dl, uric acid - 2.22mg/dl, sodium - 135, potassium - 4.15  
 LFT - Total bilirubin - 0.84, direct - 0.23 SGOT - 20, SGPT - 17,  
 Testis Biopsy - H & E stained suction shows testis surrounded by haemorrhage  
 Albumin - 2.85 gm/dl  
 All investigation reports attached with files.

**COURSE IN THE HOSPITAL AND DISCUSSION:**

(Including procedure/ Surgery performed)

Mr Remy Chacko admitted under general surgery with alleged history RTA with avulsion of skin over lower abdomen and perineal trauma with open book pelvic fracture and right femur neck fracture on 1.1.15. He was stabilized in ICU and was shifted to CT room for imaging. In CT room he developed bradycardia. Hence he was resuscitated and shifted to theatre damage control surgery. Intra op only suprapubic catheterization was done. Owing to profound blood loss, suspected coagulopathy and hypotension and atrial fibrillation he was shifted to ICU.

He received multiple transfusions (blood and blood products). Because of ongoing hematuria catheter got blocked which require aspiration for multiple times. He was stabilized in next 24 hours. There was decrease in urine output noted in this period. The creatinine went upto 4 mg/dl. He underwent NCCT after 36 hours of first exploration which showed large bladder clot in distended bladder and normal bilateral kidney and upper tract.

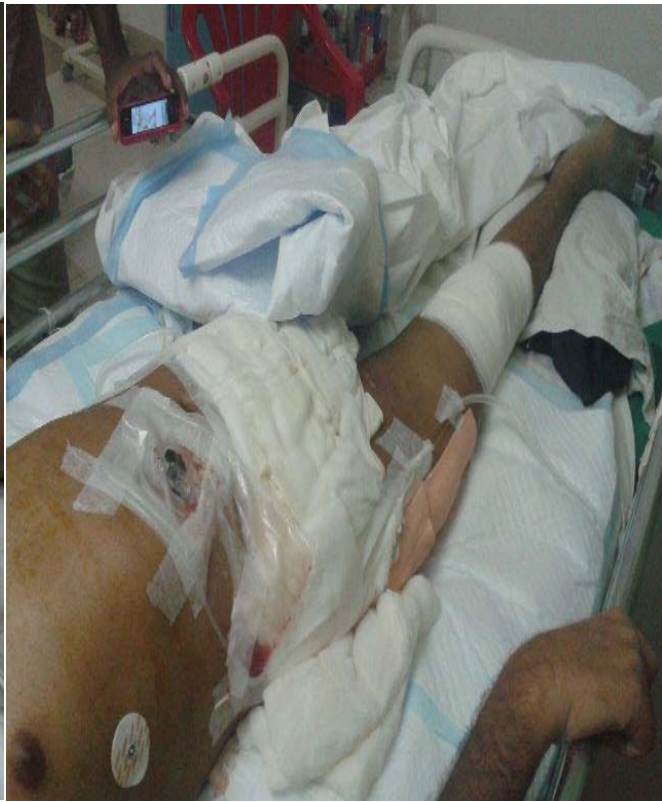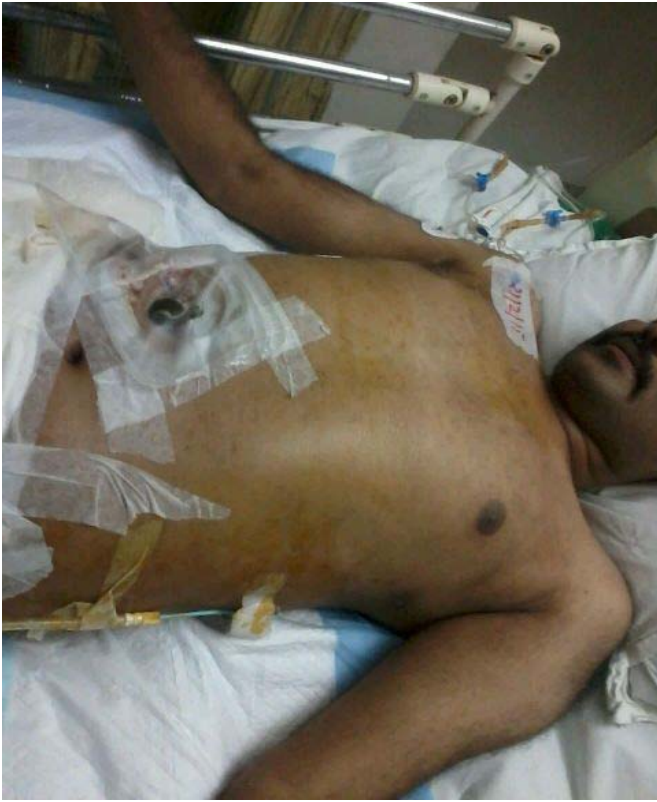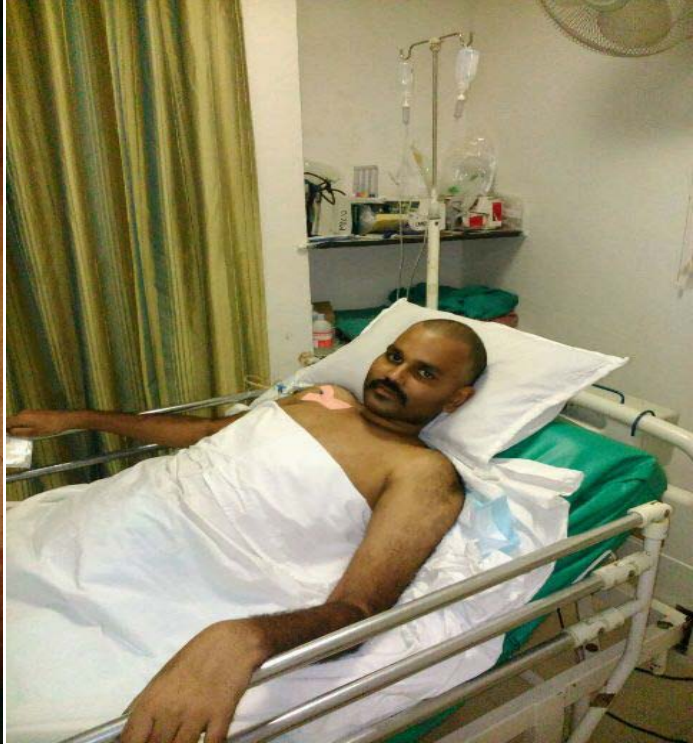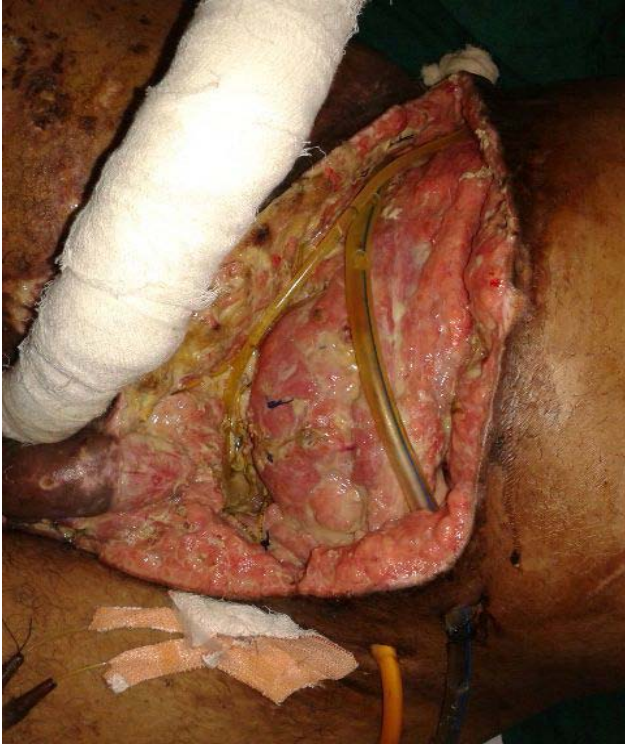He was taken for exploration, bladder was opened to remove bladder clot, inspected from inside to look for any sign of injury. Blood was seeping from the internal urethral meatus, intake urethra seen in perineum, but the pelvic diaphragm was completely torn apart. Cystoscopically catheter was placed over the guide wire and its entry confirmed through opened bladder. 18 Fr suprapubic catheters and a small drain placed and bladder was closed in 2 layers. Perineal wound was closed over the drain. Pelvis was fixed using K wires and plating (external fixator was not available).

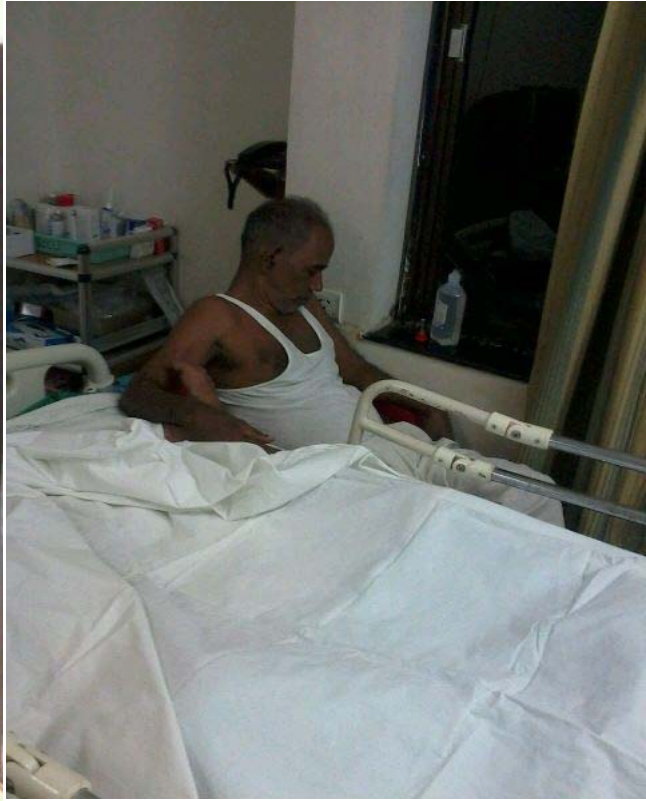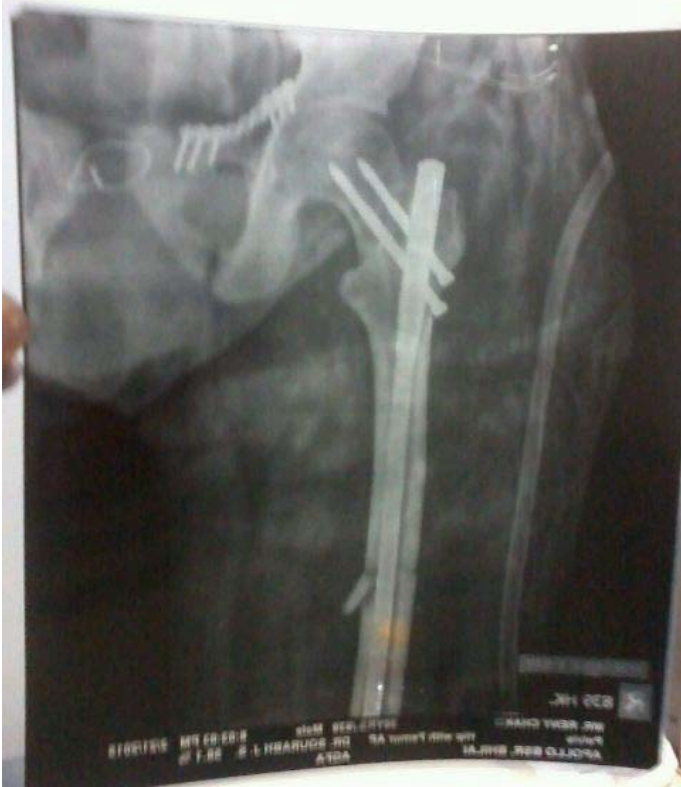By next day the urine output improved creatinine came down to normal, there was nothing in perineal drain hence it was removed after 48 hours. Both suprapubic and per urethral catheter were draining well.

On 12.01.15 the general surgeon decided to put wound management with modified vacuum suction over the exposed wound and bladder. By third day the suction drain started draining urine and both catheters were showing nil urine output.

The patient underwent exploration on 15.1.15; the whole of the suture line of bladder was leaking. Both the catheters were in situ. Bladder was opened to see for ureteric orifices. Bladder wall was edematous was bleeding on touch. Bilaterally ureteric orifices were identified and feeding tubes were placed. Bladder was closed in 2 layers.

The patient was shifted out of ICU over next 1 week. Bilateral ureteric catheters were draining, both Foley's catheter were draining in spite of that some amount of urinary seepage continued. His serum albumin was low. (1.9gm/dl). He was gradually started on oral diet. Since 19.1.15 patient started developing fever and On 22 nd the fecal soiling of perineal and bladder wound was noted. He was seen by general surgeon and planned for colostomy on same day but was differed to next day. On 23 rd Jan during exploration, the secondary suturing of perineal wound with suturing of bladder was done and colostomy was differed.





# DISCHARGE SUMMARY

NAME : 10129563

ANT : Mr. RENY CHAKO (Staff)

DISCHARGE : 27/02/2015

IP NO

: 15/104940

AGE/SEX

: 30YEAR/MALE

DATE OF ADMISSION : 01/01/2015

## DIAGNOSIS :

1. Alleged RTA with Poly trauma, Right external iliac vein injury
2. Right testicular avulsion injury
3. Perineal injury with complete disruption of pelvic diaphragm
4. Fracture pelvis, fracture acetabulum, pelvic open book fracture, pubic diastasis, fracture M/3rd femur with fracture IT right, Fracture sacrum with right SI joint disruption
5. Urinary fistula.

## HISTORY :

P/H/O - RTA on 01/01/2015 at 07:00 AM hit by unknown vehicle collision with bike.  
History of unconsciousness  
No history of DM, HTN

## CLINICAL EXAMINATION (At the time of admission)

General condition - Very poor

Pulse rate - 106/min

Blood pressure - 80/50mmHg

RS - Clear

Per abdomen - Bleeding from lower abdomen

GCS - 15/15

CVS - S1 S2 (+)

- Open pelvis injury, injury to pelvis/ penis/ testis/ Scrotum / Bladder seen in fact.
- Pubic bone fracture, Right femur fracture
- Skin laceration to left side of thigh

## TREATMENT GIVEN :

1. Exploration of perineal/ Pelvis injury intraperitoneal lavage with pelvic and perineal wound packing in view of damage control with suprapubic catheterisation 01/01/2015 by AKS/ AVD.
2. Pack removal suprapubic cystotomy with clot evaluation and per urethral and suprapubic catheterisation Pubic symphysis stabilisation with plating right sup. pubic rami (AVD/AKS/SS)
3. Bladder repair with bilateral ureteric catheterisation on 15/01/2015 by AVD/AKS
4. Exploration of main OR and perineal and abdominal washing, Secondary closure of bladder leak 23.1.15 AVD/AKS (colostomy deferred)
5. Bladder repair with bilateral ureteric catheterisation and bilateral PCN placement on 31/01/2015 by AVD/AKS
6. Exploration of main OR and perineal and abdominal washing 10.2.15 AKS/AVD (colostomy deferred)
7. Abdominal wound washing and transverse colostomy done on 21/02/2015 by Dr. AKS



Ca++ :-5.50, Mg++ :-0.89

D-Dimer - 2750

PTT - 18.6, INR - 1.61, APTT - 27.2

Suction Tube culture - Klebsiella pneumonia

Tracheal culture - Pseudomonas species

Testis Biopsy - H & E stained suction shows testis surrounded by haemorrhage

Albumin - 1.99

BUN - 30.8

Swab culture - Klebsiella pneumonia

All investigation reports attached with files.

### **COURSE IN THE HOSPITAL AND DISCUSSION**

**(Including procedure/ surgery performed) :**

A 30 years old male patient presented with alleged history of RTA on 01/01/2015 at 7:00 AM hit by unknown vehicle. History of unconsciousness. Patient shifted in ICU treatment under Dr. A.K Shrivastava. Required investigation done. Surgery done on 01/01/2015, 07/01/2015, 23/01/2015, 10/02/2015 & 21/02/2015 by Dr. A.K Shrivastava. Post operative patient recovered well. Patient discharged on haemodynamically stable.

### **PROCEDURE / SURGERY PERFORMED :**

- 1) Exploration of perineal/ Pelvis injury done on 01/01/2015 by Dr. A.K Shrivastava.
  - Vessel repair right external iliac vein done on 01/01/2015 by Dr. A.K Shrivastava.
  - Abdominal exploration done on 01/01/2015 by Dr. A.K Shrivastava.
  - Lavage done 01/01/2015 by Dr. A.K Shrivastava.
- 2) Debridement done 07/01/2015 by Dr. A.K Shrivastava.
- 3) Secondary closure of bladder leak with secondary suturing of perineal wound with lavage done on 23/02/2015 by Dr. A.K Shrivastava/Dr. AVD.
- 4) Exploration of main wound & perineal and abdomen washing done 10/02/2015 AKS/AVD.
- 5) Transverse colostomy done on 21/02/2015 by Dr. A.K Shrivastava.

### **CONDITION OF THE PATIENT AT THE TIME OF DISCHARGE :**

Haemodynamically stable.

### **ADVICE ON DISCHARGE :**

**DIET** : - Normal

**PHYSICAL ACTIVITY** : As tolerated.





... was not healing well; the relatives were explained regarding the need for further expertise



Navin Daruka was consulted regarding the urinary fistula; it was decided to further divert urine by placing bilateral PCNs. Hence he was taken to theatre on 31.01.15. The ureteric stents were changed to large bore, bilateral PCNs were placed and bladder was closed. Post PCN placed, the urine leak was reduced. However the possibility of leaking of urine around per urethral catheter was kept in mind. The urethral catheter was removed after 3 days and the urine leak reduced drastically. He was kept on liquid diet and anti diarrheal medicines. Over the next week and he was planned for femur nailing. On 8.2.15 the fecal soiling reappeared, general surgeon saw the wound but differed colostomy for 2 days in view of possibility pseudo membranous colitis. The urinary leak was nil. The relatives explained regarding the possibility of bladder fistula sec. to intense inflammation of bladder wall. Mean while the right PCN was stopped draining and was noticed to come out in subcutaneous space hence it was removed. On 10.2.15 he was taken to theatre the perineum and perianal region explored by general surgeon. But he decided against colostomy.

On 13.2.15 patient was again found to have fecal soiling, bladder wall was intensely inflamed. Relatives were explained regarding possibility of bladder opening and the need for fecal diversion. On 19.2.15 the bladder integrity was checked using diluted methylene blue under antibiotics cover. After 150 ml diluted methylene blue instilled there was leakage of urine from the urethral meatus rest anterior bladder wall was appeared to be normal. Bilateral ureteric tubes were clamped and the suprapubic catheter was draining well without any leak.

On 21.2.15 he was taken by general surgeon for perineal wound wash and colostomy. Post colostomy he was shifted to recovery where he was noticed of urinary leak from the bladder wall. The dressing was changed; bilateral ureteric catheters were again connected to uroscac along with SPC.

On 24.02.15 he was again taken for exploration, there was 1cm rent in anterior bladder wall. Rest of the bladder wall healed very well. The bladder was opened. Left ureteric catheter was seen in bladder. Both the ureteric catheter placed in ureter and bladder is closed in two layers. He is referred to higher centre for further treatment.

**DISCHARGE MEDICATION:**

- High protein diet
- Catheter care
- Bilateral ureteric catheter care and avoid kinking
- Tab Cefixime 200mg twice daily for 7 days.
- Tab Ultracet 1 tab as required for pain
- Tab Paracetamol 500 mg once as required for fever.

**FOLLOW UP** : - Review as required

**URGENT CARE** :

**HOW TO OBTAIN**

In the emergency, contact casualty medical officer. Emergency contact No: Phone: 0788-4085100-299. This discharge summary was explained to me in my own language which I understand and handed over to me by the consultant.

Signature of Patient/  
Patient relatives:

*Ashwini*  
Signature of the Doctor

Registrar/Resident/C.M.O.



### DISCHARGE ON REQUEST SUMMARY

Reg No.	10129563	IP No.	15/104940
Patient	Mr. Rony Chako(Staff)	Bed Category	Twin Room
Age / Sex	30 Yrs/Male	Bed No.	223-A
Consultant	Dr. ASHISHKUMAR SHRIVASTAVA	DOA	01/01/2015 08:57
Surgery Date	23/01/2015 15:13	DOD	28/02/2015 15:59
Address	VAZT TUPARBIL SPURAM KURICHI Kerala INDIA		

#### DIAGNOSIS :

Poly trauma open pelvis injury with iliac vein external injury, Bladder injury, Testicular & urethral/ Pelvis injury  
 Facial soiling of perineal wound with bladder leak, Perineal injury,  
 Right femur fracture

#### HISTORY :

ATRO RTA on 01/01/2015 at 07:00 AM hit by unknown vehicle collision with bike  
 History of unconsensiousness  
 No history of DM HTN

#### CLINICAL EXAMINATION :

General condition - Very poor  
 Pulse rate - 106/min  
 Blood pressure - 80/50mmHg  
 RS - Clear  
 Per abdomen - Bleeding from lower abdomen  
 GCS - 15/15  
 CVS - S1 S2 (+)  
 per pelvis injury, injury to pelvis/ penis/ testis/ Scrotum / Bladder seen in fact.  
 Pubic bone fracture, Right femur fracture.

#### TREATMENT GIVEN :

- 1) Exploration of perineal/ Pelvis injury done on 01/01/2015 by Dr. A.K Shrivastava.  
 Vessel repair right external iliac vein done on 01/01/2015 by Dr. A.K Shrivastava.  
 Abdominal exploration done on 01/01/2015 by Dr. A.K Shrivastava.  
 Lavage done 01/01/2015 by Dr. A.K Shrivastava
- 2) Debridement done 07/01/2015 by Dr. A.K Shrivastava.
- 3) Secondary closure of bladder leak with secondary suturing of perineal wound with lavage done on 23/01/2015 by Dr. A.K Shrivastava/Dr. AVD.
- 4) Exploration of main wound & perineal and abdomen washing done 10/02/2015 AKS/AVD.
- 5) Transverse colostomy done on 21/02/2015 by Dr. A.K Shrivastava

#### INVESTIGATIONS :

CBC - Hb - 8.4, TLC - 11460, platelet count - 73000  
 RFT - Urea - 114, creatinine - 4.10, uric acid - 7.59, sodium - 148, potassium - 4.80  
 LFT - Total bilirubin - 2.6, direct - 1.0, SGOT - 229, SGPT - 45,  
 ECG - Done



# DISCHARGE SUMMARY



PATIENT NAME : 10129563  
CONSULTANT : Mr. RENY CHAKO (Staff)  
DATE OF DISCHARGE : 27/02/2015  
Dr. A.K.SHRIVASTAVA  
Dr. AMIT V DESHPANDE  
Dr. SOURABH J. SHIRGUPPE

IP NO : 15/104940  
AGE/SEX : 30YEAR/MALE  
DATE OF ADMISSION : 01/01/2015

## DIAGNOSIS :

1. Alleged RT A with Poly trauma, Right external iliac vein injury
2. Right testicular avulsion injury
3. Perineal injury with complete disruption of pelvic diaphragm
4. Fracture pelvis, fracture acetabulum, pelvic open book fracture, pubic diastasis, fracture M/3rd femur with fracture IT right, Fracture sacrum with right SI joint disruption
5. Urinary fistula.

## HISTORY :

M/H/O - RTA on 01/01/2015 at 07:00 AM hit by unknown vehicle collision with bike.  
History of unconsciousness  
No history of DM, HTN

## CLINICAL EXAMINATION (At the time of admission)

General condition - Very poor

Pulse rate - 106/min

Blood pressure - 80/50mmHg

RS - Clear

Per abdomen - Bleeding from lower abdomen

GCS - 15/15

CVS - S1 S2 (+)

- Open pelvis injury, injury to pelvis/ penis/ testis/ Scrotum /, Bladder seen in fact.
- Pubic bone fracture, Right femur fracture
- Skin laceration to left side of thigh

## TREATMENT GIVEN :

1. Exploration of perineal/ Pelvis injury intraperitoneal lavage with pelvic and perineal wound packing in view of damage control with suprapubic catheterisation 01/01/2015 by AKS/ AVD.
2. Pack removal suprapubic cystotomy with clot evaluation and per urethral and suprapubic catheterisation. Pubic symphysis stabilisation with plating right sup. pubic rami (AVD/AKS/SS)
3. Bladder repair with bilateral ureteric catheterisation on 15/01/2015 by AVD/AKS
4. Exploration of main OR and perineal and abdominal washing. Secondary closure of bladder leak 23.1.15 AVD/AKS (colostomy deferred)
5. Bladder repair with bilateral ureteric catheterisation and bilateral PCN placement on 31/01/2015 by AVD/AKS
6. Exploration of main OR and perineal and abdominal washing 10.2.15 AKS/AVD (colostomy deferred)
7. Abdominal wound washing and transverse colostomy done on 21/02/2015 by Dr.AKS





**Apollo BSR Hospitals**  
touching lives

**DISCHARGE MEDICATION :**  
Rx :  
Referred to higher center.




Injection - Amikacin 750 mg IV once daily  
Injection - Tramadol 1amp IV once daily  
Injection - Fortum 1gm IV thrice daily  
Tablet - Paracetamol 500 mg SOS  
Injection - Pantoid 40 mg IV twice daily  
Tablet - Tropan 5mg twice daily

**FOLLOW UP**  
- Review after

**URGENT CARE**

**HOW TO OBTAIN :**  
In the emergency, contact casualty medical officer, Emergency contact No: Phone: 0788-4085100-299.  
This discharge summary was explained to me in my own language which I understand and handed over to me by the consultant.

Signature of Patient/Patient relatives:      Signature of the Doctor      Registrar/Resident/C.M.O.

**Apollo BSR Hospitals**  
touching lives

**TO WHOMSOEVER IT MAY CONCERN**

Mr. Remy Chacko, S/o Mr. THomes Chacko, Aged 30 Years Male, Dialysis technician at Apollo BSR Hospital, Bhilai, (C.G.) Permanent resident of Vazhaparambil House, P.O. S-Puram,, Kurichy Panchayath, Kottayam District, Kerala is currently undergoing treatment at Apollo BSR Hospital, Bhilai (C.G.) Since 1/1/2015.

Diagnosis-Extensive Polytrauma, following road traffic accident with open lower abdomen injury, compound fracture pelvis & right femur, with urinary bladder, urethral, right testicular, penile injuries with vascular injuries, with sepsis with Multi Organ Dysfunction Syndrome (MODS).


He is being attended to, beside Consultant General Surgeon, by Cardio Vascular, Orthopedic, Urological Surgeons, as well as Nephrologists, General Physician and Critical Care Medical Team.

He has undergone, multiple blood transfusions, multiple extensive surgeries involving the above multi specialty Surgeons on 1/1/2015, 3/1/2015, 7/1/2015 and 15/1/2015.

He is likely to require prolonged hospital care, expensive medication and materials.  
He is likely to require multiple Plastic Surgical surgeries in due course.

Date : 19-01-2015

*Ashish*  
Dr. Ashish Kumar Srivastava  
MS, Consultant General Surgeon,  
Apollo BSR Hospital,  
Junwani Road, Smiriti Nagar  
Bhilai (C.G.)  
PH : 0788-4085100



**MEDICAL EMERGENCY**  
24x7 2299999

**APOLLO BSR HOSPITAL**  
A UNIT OF BSR SUPERSPECIALTY HOSPITALS

Junwani Road, Smiriti Nagar, Bhilai, (C.G.), INDIA. Ph : 0788-4085100-299 | Fax : 0788-4085132 | Email : info@apollobsr.com | www.apollobsr.com